

# Lecture 6



Text figures from:

MD: Moore and Dalley, Clinically Oriented Anatomy 5th Edition  
2006 Lippincott Williams and Wilkins

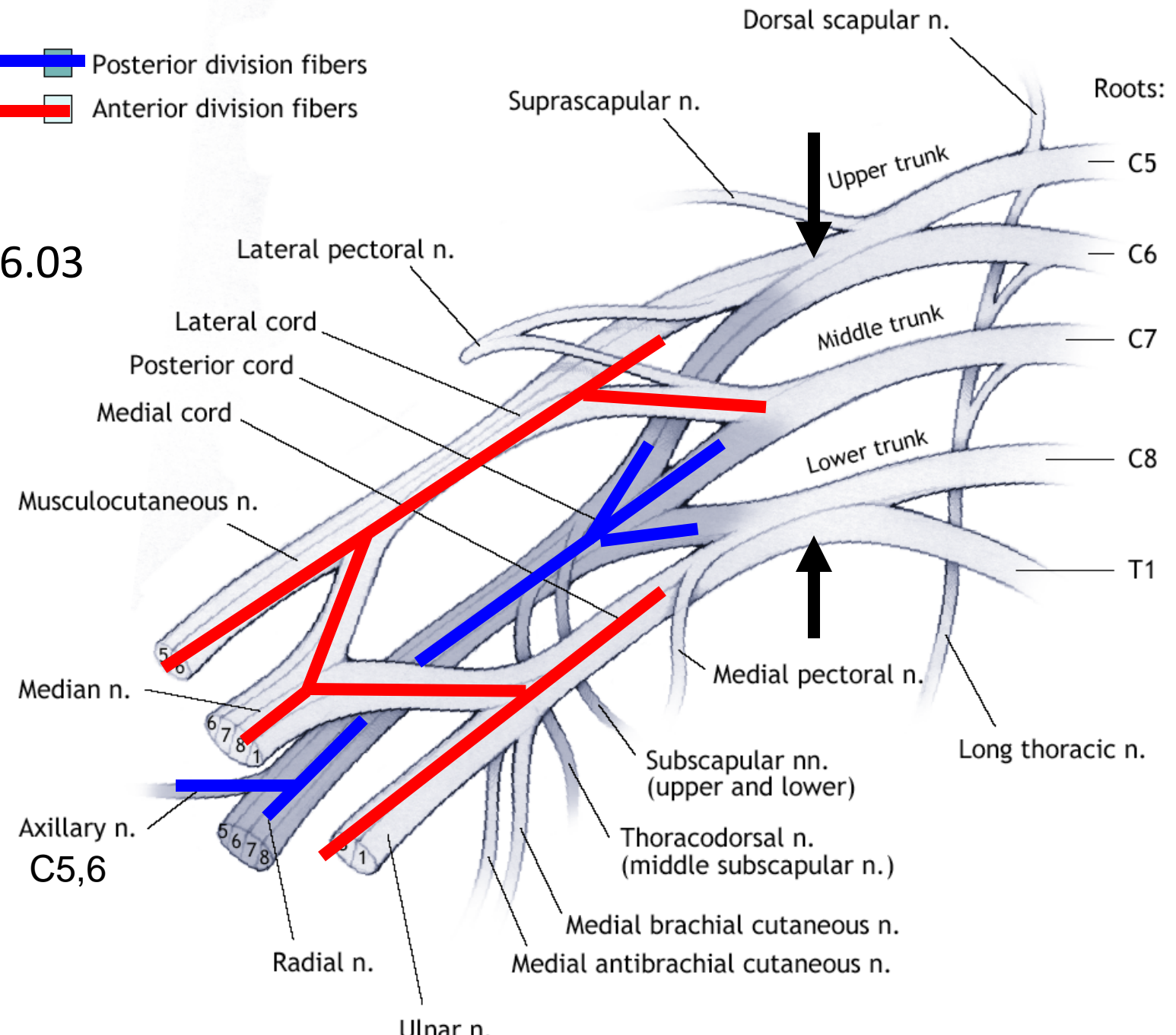
G: Drake, Vogl and Mitchell, Gray's Anatomy for Medical Students  
2005 Elsevier

NP: Netter, Atlas of Human Anatomy 5 Edition,  
Elsevier, 2011

RM: White, USMLE Road Map Gross Anatomy 2nd Ed.  
McGraw-Hill

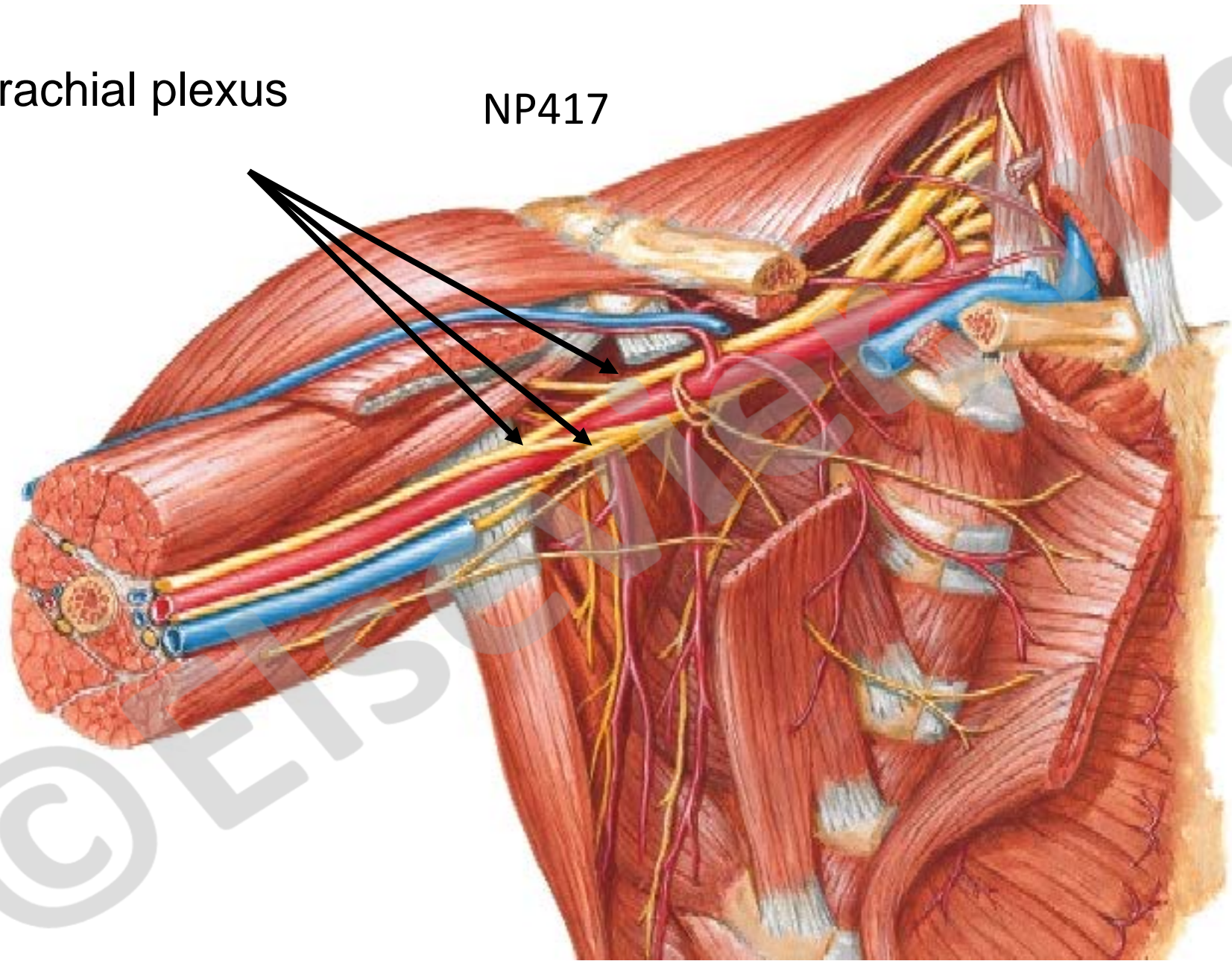
-  Posterior division fibers
-  Anterior division fibers

RM6.03



Brachial plexus

NP417

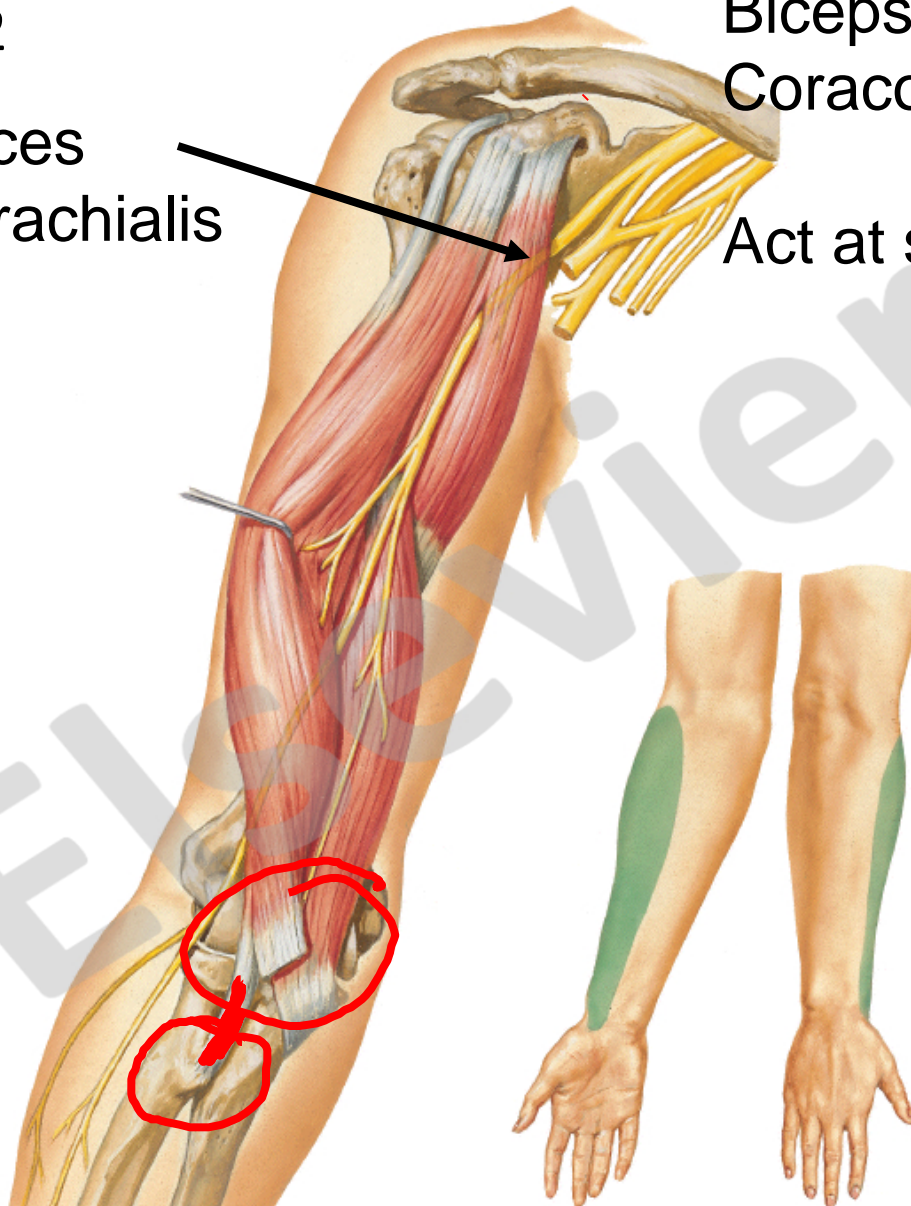


Musculocutaneous Nerve C5, C6 **anterior arm muscles:**  
Biceps brachii, Brachialis,  
Coracobrachialis

NP462

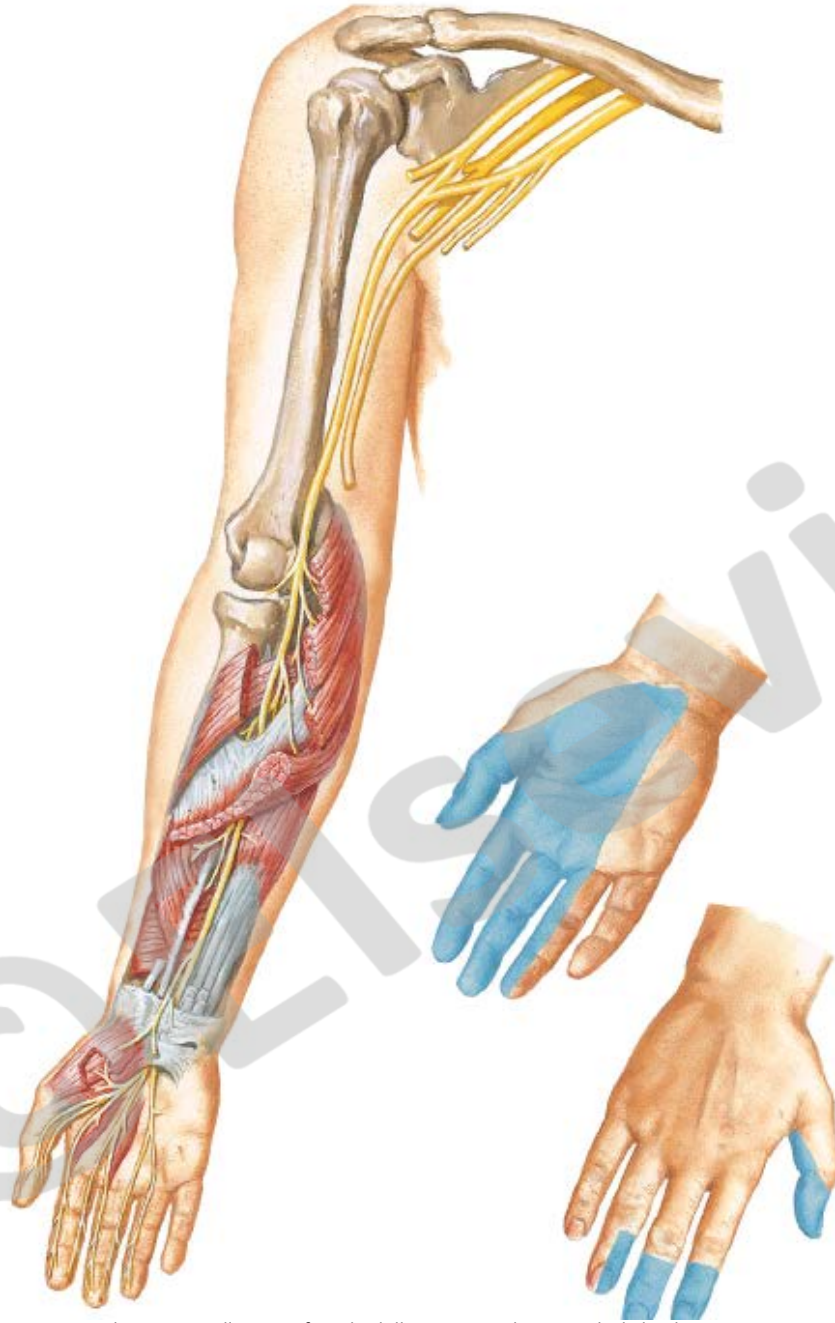MC pierces  
coracobrachialis

Act at shoulder and elbow





## Median Nerve



C6- T1

NP463

All but 1 and 1/2

**Anterior forearm muscles,**  
Thumb (thenar muscles) and  
2 lumbricals in hand

Act at elbow, wrist, thumb  
and fingers

# Ulnar Nerve

C8, T1

NP464

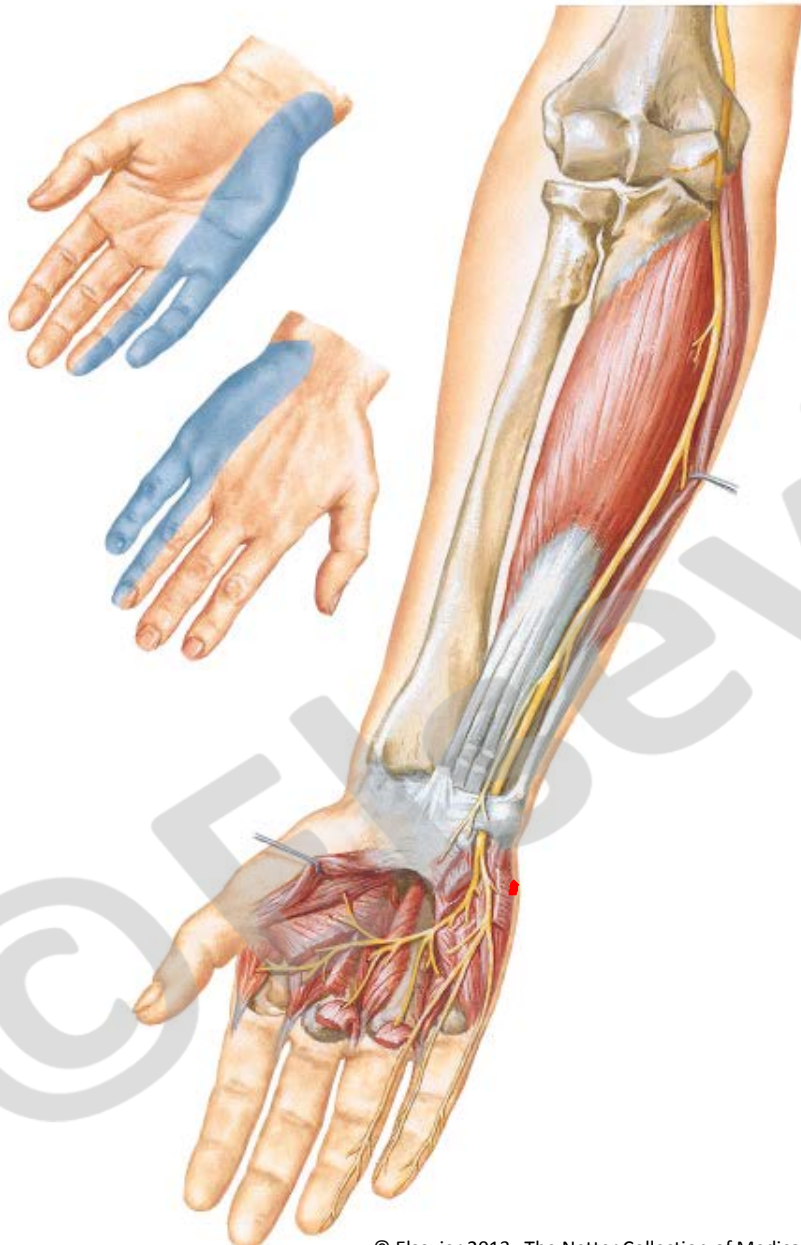
1 and 1/2 forearm muscles

All **intrinsic hand muscles**

except those innervated

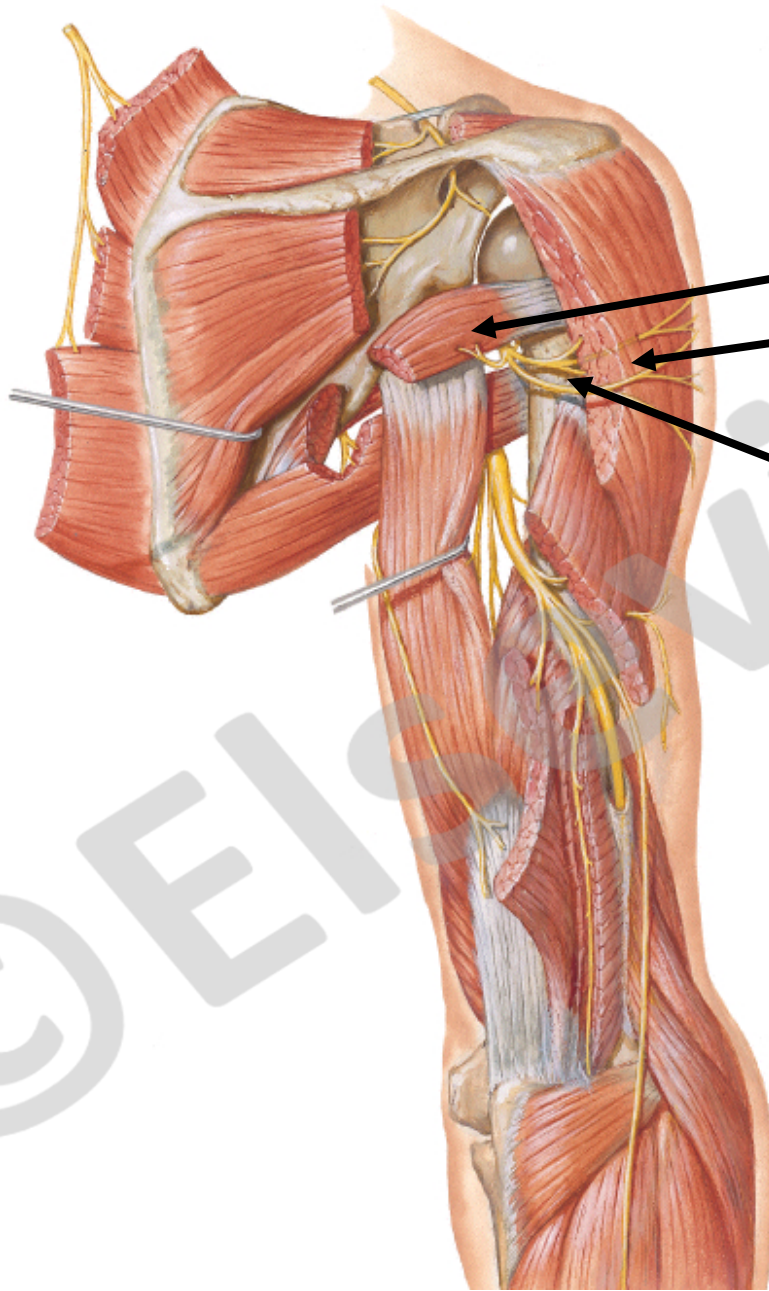
by median nerve

Act mainly on thumb and fingers



# Scapular, Axillary, and Radial Nerves Above the Elbow

NP465



Innervates  
Teres minor and  
Deltoid

Axillary nerve C5, C6

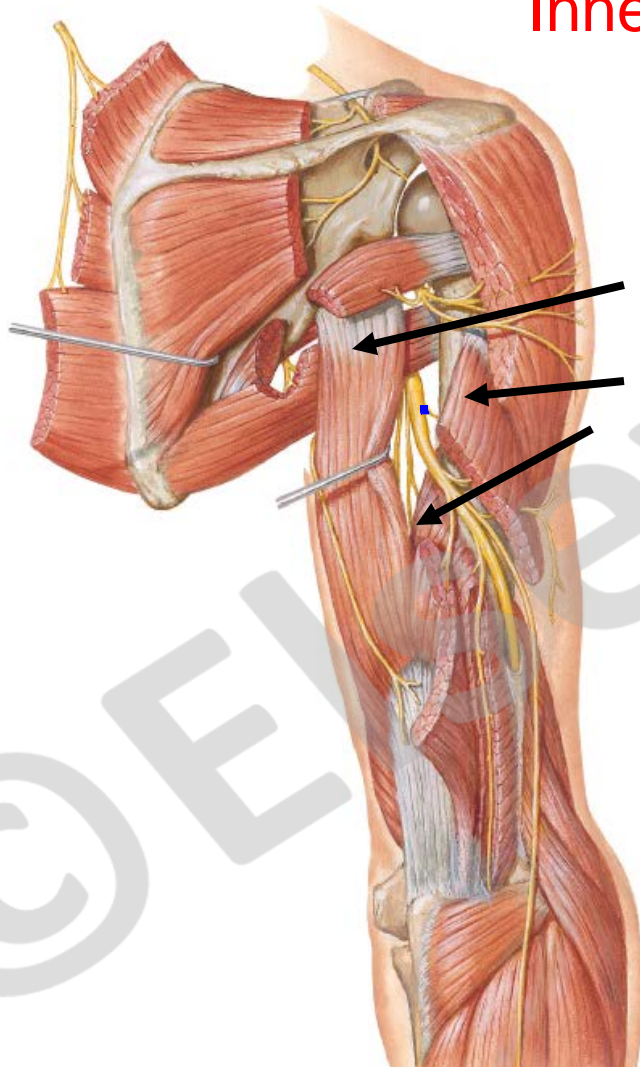
Act only at shoulder



# Radial nerve C5,6,7,8

NP465

Scapular, Axillary, and Radial Nerves Above the Elbow



Innervates:

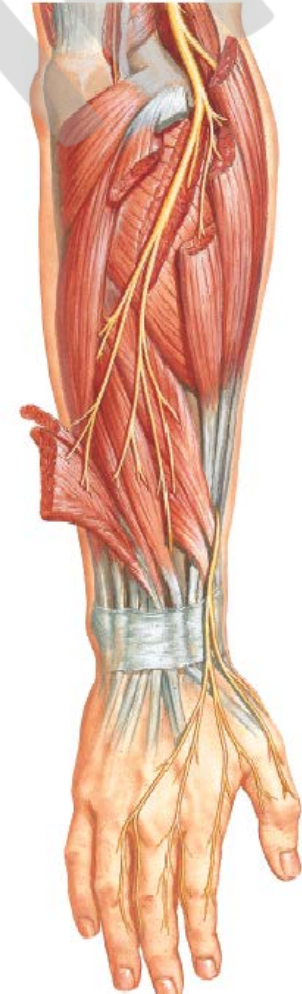Triceps  
Long  
Lateral  
Medial  
Heads

Posterior  
Forearm  
muscles

Act at shoulder, elbow  
wrist, thumb and  
fingers

NP466

Radial Nerve in the Forearm





G7.10

